Exp Brain Res (2004) 155: 115–119
DOI 10.1007/s00221-003-1738-4

RESEARCH NOTE

Burkhard Pleger · Martin Tegenthoff · Peter Schwenkreis · Frank Janssen · Patrick Ragert · Hubert R. Dinse · Birgit Völker · Michael Zenz · Christoph Maier

Mean sustained pain levels are linked to hemispherical side-to-side differences of primary somatosensory cortex in the complex regional pain syndrome I

Received: 9 April 2003 / Accepted: 29 November 2003 / Published online: 27 January 2004
© Springer-Verlag 2004

Abstract Chronic back pain as well as phantom-limb pain is characterized by a close relationship between the amount of cortical reorganization and the magnitude of pain. In patients with positively assessed complex regional pain syndrome type I (CRPS I), we found a positive correlation between representational changes of primary somatosensory cortex (SI) and mean sustained pain levels. We investigated seven right-handed patients with CRPS I of one upper limb by means of somatosensory evoked potential (SSEP) mapping. Cortical representation of the CRPS-affected hand was significantly smaller than that of the contralateral healthy hand, giving rise to a substantial side difference. Subjective pain levels experienced over the last 4 weeks were estimated according to the visual analogue scale (VAS). Individual expansion of hand representation contralateral to the CRPS-affected limb was significantly correlated with mean pain intensity. Accordingly, low pain levels were linked to small representational side-to-side differences, while subjects with a distinctive hemispherical asymmetry reported the highest pain levels. Follow-up studies using functional imaging methods might be instrumental in providing a better understanding of this issue.

Keywords Pain · Complex regional pain syndrome · Somatosensory cortex · SSEP mapping · Cortical plasticity

B. Pleger · M. Tegenthoff (✉) · P. Schwenkreis · F. Janssen
Department of Neurology, BG-Kliniken Bergmannsheil, Ruhr University Bochum,
Buerkle-de-la-Camp Platz 1,
44789 Bochum, Germany
e-mail: martin.tegenthoff@ruhr-uni-bochum.de
Tel.: +49-234-3026808
Fax: +49-234-3026888

P. Ragert · H. R. Dinse
Institute for Neuroinformatics, Department of Theoretical Biology, Ruhr University Bochum,
44780 Bochum, Germany

B. Völker · C. Maier
Department of Pain Treatment, BG-Kliniken Bergmannsheil, Ruhr University Bochum,
Buerkle-de-la-Camp Platz 1, 44789 Bochum, Germany

M. Zenz
Department of Anaesthesiology, Intensive Care and Pain Treatment, BG-Kliniken Bergmannsheil, Ruhr University Bochum,
Buerkle-de-la-Camp Platz 1,
44789 Bochum, Germany

Introduction

Pain-related reorganization of the primary somatosensory cortex (SI) has been described in patients following arm amputations and using neuromagnetic imaging techniques (Flor et al. 1995), as well as in chronic back pain (Flor et al. 1997).

In amputees with phantom limb pain, cortical representation of the lip contralateral to the amputated upper limb was displaced towards the hand representation depending on the individual pain intensity. Elimination of experienced phantom limb pain by means of anaesthesia was paralleled by a very rapid reversal of cortical reorganization in the somatosensory cortex (Birbaumer et al. 1997). These results in amputees suggested that cortical reorganization processes were linked to the development of phantom limb pain.

Complex region pain syndrome following peripheral injury occurs without (CRPS type I) or with nerve injury —CRPS type II (Baron and Wasner 2001; Birklein and Handwerker 2001; Schott 2001). Patients present various symptoms including peripheral disturbances of skin blood flow, edema, trophic changes, progressive stiffness of distal joints and an increased bone metabolism (Veldman et al. 1993; Bruehl et al. 2002). However, pain and allodynia are the aspects that are most difficult to treat (Schwartzman 1993).

In a recent study using magnetoencephalography (MEG), no correlation between the amount of pain (estimated directly before measurement) and hemispheri-

cal side-to-side differences of SI representation was found (Juottonen et al. 2002). The aim of the present study was to assess whether changes in the contralateral hand representation in SI are linked to sustained pain level experienced over 4 weeks. Seven patients with positively assessed CRPS I and seven healthy volunteers were subjected to somatosensory evoked potential mapping (SSEP).

Materials and methods

Patients

The study was approved by the Ethics Committee of the Ruhr University of Bochum and was performed in accordance with the 1964 Declaration of Helsinki. All patients and control subjects gave their informed written consent. We investigated somatotopic expansion of the hand representation in SI by SSEP mapping in seven right-handed patients (three female, four male; age: mean 40 years; range 19–64 years) suffering from spontaneous pain due to definite CRPS type I of one upper limb and seven right-handed controls (six female, one male, age: mean 28 years; range 20–45 years; Mann-Whitney U-test CPRS vs control: $Z=-1.35$, $p=0.2$). In CRPS I a definable nerve lesion can be excluded (Stanton-Hicks et al. 1995). Before their participation in the SSEP mapping all patients underwent electroneurographic and neurological examination. All patients exhibited typical symptoms for CRPS including an increased bone metabolism as revealed by three-phase scintigraphy. Patients with cutaneous damage and massive oedema of the CRPS affected hand were excluded. Conventional somatosensory potential measurement during stimulation of the ulnar and median nerve was performed to rule out that the presence of temperature changes, swelling and sweating of the CRPS-affected limb could affect transmission of the electrical stimuli to the nerve during SSEP measurements. The duration of CRPS I was between 1 and 12 months (mean 5.7 months). Patients had to estimate their experienced pain intensity based on a visual analogue scale (VAS) from 0 (= no pain) to 10 (= most extreme pain) on two occasions: Firstly, the mean pain intensity experienced during the last 4 weeks and, secondly, that pain intensity felt directly before SSEP measurement. Patients also rated the degree of immobilization during the last 4 weeks in percent (0 = no immobilization, 100 = complete immobilization). Patients had not taken any centrally acting drugs for at least 48 h before participating in the study.

SSEP mapping

SSEP mapping was performed with a non-painful electrical stimulation of the median and ulnar nerve (pulse duration: 0.1 ms; repetition rate: 3 Hz; stimulation intensity was calibrated 2.5 times above sensory threshold). We recorded electrical potentials in epochs from 30 ms before to 100 ms after the stimulus with band-pass filtering between 1 and 1,000 Hz and a sampling rate of 5,000 Hz. For each session we measured 1,600 stimulus-related epochs. Epochs were digitally filtered, using a band pass filter (20–500 Hz, 24 dB/Oct) with reference to a common average and averaged using Neuroscan software (Scan 4.1). Source reconstruction for the N20 SSEP component was performed, based on a single rotating dipole model in a spherical volume conductor using ASA software (ANT software, The Netherlands). Recordings were made using a 32-channel EEG system (Neuroscan, USA). Electrodes were positioned over both hemispheres according to the 10–20 system. In order to take the individual shape of the subject's head into account, we measured electrode positions with a 3D digitizer (Polhemus, Colchester, VT).

The polar angle difference between the N20 dipoles after median and ulnar nerve stimulation was used as a parameter to describe the dimension of the cortical hand representation. The dipole coordinates were therefore projected onto an adjusted 3D coordinate system (y-axis: joined acoustic meati of both ears; x-axis: joined centre point of y-axis and origin of nasion; z-axis: joined centre point and vertex). The polar angle of each nerve representation was calculated by referring the connection between dipole position and y-axis to z-axis.

While in only four patients the CRPS impairment affected the dominant hand, we evaluated the influence of hand dominance on cortical representational changes. We did this by comparing the mean polar angle difference representing the cortical hand representation of the non-affected dominant hemisphere ($n=3$) with the one on the non-affected non-dominant hemisphere ($n=4$).

All electrophysiological data were statistically analyzed using the Wilcoxon signed rank test, Mann-Whitney U-test and non-parametric correlation analysis (Kendall-tau-b, Spearman's rho). The evaluation of the SSEP data was performed independently from the exploration of the clinical data by an external anaesthesiologist.

Results

SSEP mapping

The results of somatosensory potential measurement in all seven patients showed latencies and amplitudes of the N20 component without any side-to-side differences [median-nerve: mean latency 20.1±1.3 ms ("CRPS hemisphere") vs 20.3±1.1 ms ("healthy hemisphere"), $Z=-0.21$, $p=0.83$, mean amplitudes 13.2±6 mA ("CRPS hemisphere") vs 11.3±2.9 mA ("healthy hemisphere"), $Z=-0.93$, $p=0.35$; ulnar nerve: mean latency 21.1±1.4 ms ("CRPS hemisphere") vs 20.9±1.2 ms ("healthy hemisphere"), $Z=-0.81$, $p=0.41$, mean amplitudes 6.7±1.8 mA ("CRPS hemisphere") vs 7±2.2 mA ("healthy hemisphere"), $Z=-0.59$, $p=0.55$, Wilcoxon signed rank test].

However, the differences between the polar angles of the N20-dipole locations of both nerve representations were significantly smaller on the CRPS-associated hemisphere [median nerve N20-dipole: 27°±4° ("CRPS hemisphere") vs 28°±5° ("healthy hemisphere"); ulnar nerve N20-dipole: 27°±2° ("CRPS hemisphere") vs 26°±2° ("healthy hemisphere"); difference between the median and ulnar nerve polar angle: 1.1°±1° ("CRPS hemisphere") vs 3.2°±1° ("healthy hemisphere"); $Z=-2.36$, $p=0.018$; Wilcoxon signed rank test; see Fig. 1 and Table 1 for individual data].

These findings were independent of handedness (dominant hemisphere: 3°±1°; non-dominant hemisphere: 4°±1°; Wilcoxon signed rank test: $Z=-1.17$, $p=0.28$).

In the control group we found no significant differences between dominant left and non-dominant right hemisphere (difference between the median and the ulnar nerve polar angle: dominant hemisphere: 2.7°±1.3°; non-dominant hemisphere: 2.9°±1.4°; Wilcoxon signed rank test: Z −0.69, $p=0.5$).

While the hand's representation on the hemisphere contralateral to the CRPS-affected side was significantly smaller than in control subjects ("CRPS hemisphere" vs dominant hemisphere: $Z=-2.1$, $p=0.03$ and vs non-dom-

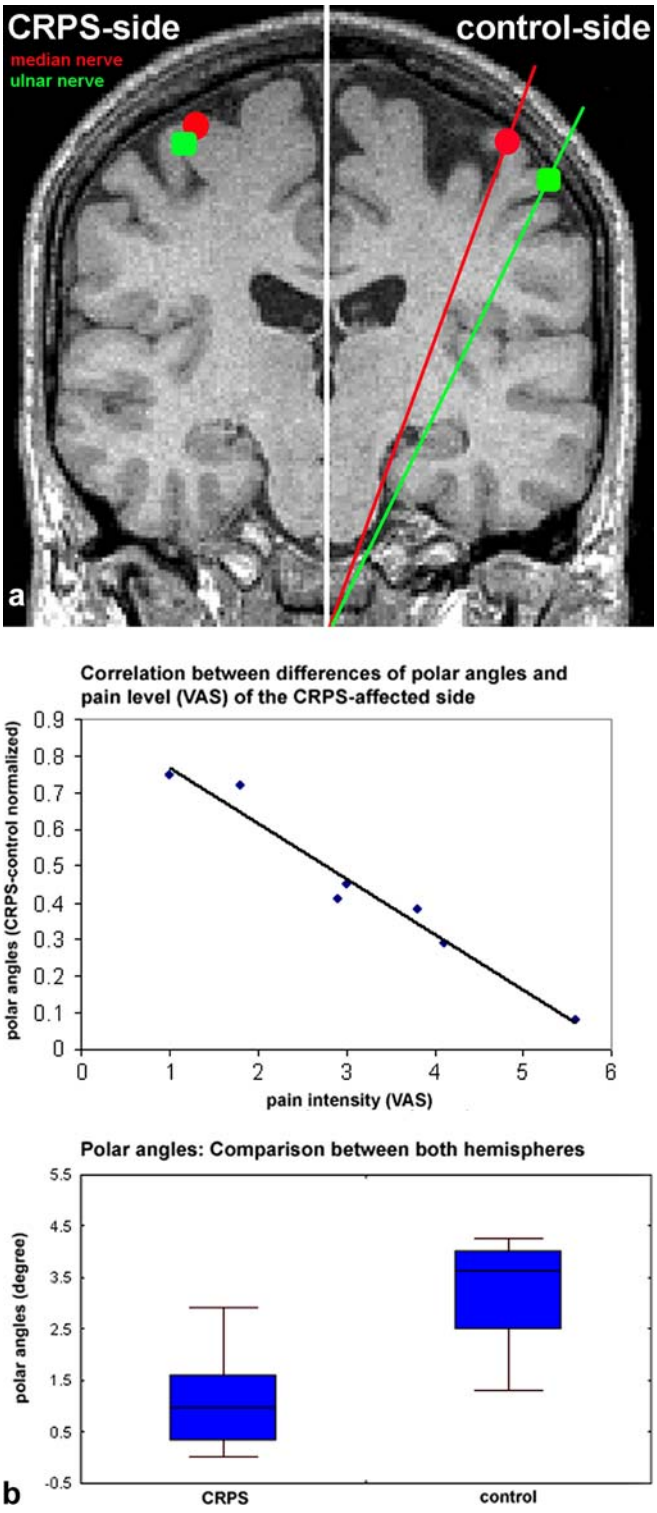

Fig. 1 *Left* The cortical representations of the median (*red*) and ulnar nerve (*green*) were projected onto a coronal magnetic resonance imaging slice. The average positions of the N20-dipoles are given by the polar angles showing a larger hand representation on the control hemisphere than on the CRPS-associated hemisphere. *Right* The scatter plot (*figure above*) shows the correlation between the differences of polar angles and mean pain level (Kendall-Tau-b: $r=-0.905$; $p=0.004$; Spearman's rho: $r=-0.964$; $p<0.001$). Box-whisker plot (*below*) demonstrates the differences between median and ulnar nerve N20-dipole-locations of the CRPS corresponding hemisphere in comparison with the non-affected contralateral side (*centre line within the box* gives the median of data; *top and bottom of the box* give the 25th and 75th percentiles; *top and bottom of the whisker* give maximum and minimum, respectively; $Z=-2.36$, $p=0.018$; Wilcoxon signed rank test)

inant hemisphere: $Z=-2.2$, $p=0.03$), data received during measurement of "healthy hemisphere" were found in normative limits ("healthy-hemisphere" vs dominant hemisphere: $Z=-0.9$, $p=0.4$, and vs non-dominant hemisphere: $Z=-0.6$, $p=0.6$, Mann-Whitney U-test).

Correlation between pain intensity and cortical representation

Non-parametric correlation analysis (Kendall-tau-b, Spearman's rho) revealed a significant correlation between the expansion of hand representation in SI contralateral to the CRPS-affected limb expressed by the changes of the polar angles (CRPS-control normalized) and the mean pain level (VAS) (Kendall-tau-b: $r=-0.905$; $p=0.004$; Spearman's rho: $r=-0.964$; $p<0.001$) (Fig. 1b).

On the other hand, the same correlation analysis revealed no correlation between the somatosensory hand representation and the current pain intensity (VAS) evaluated on the day when SSEP mapping was performed (Kendall-tau-b: $r=-0.143$; $p=0.65$; Spearman's rho: $r=-0.214$; $p=0.64$) and the degree of immobilization of the CRPS-affected hand (Kendall-tau-b: $r=0.451$; $p=0.17$; Spearman's rho: $r=0.473$; $p=0.28$).

Discussion

In summary, our SSEP data revealed a significantly smaller difference of polar angles between the median and the ulnar nerve N20-dipole localizations on the somatosensory cortex contralateral to the limb affected by CRPS I. This indicates a smaller representational field of the CRPS-affected hand in SI than contralateral to the non-affected hand and on both hemispheres of healthy volunteers. Most importantly, the observed reduction was significantly correlated with the degree of the CRPS-induced pain experienced continuously for the 4-week period before SSEP measurement. Accordingly, low pain levels were associated with small changes in SI, whereas subjects with higher pain intensity levels exhibited a marked asymmetry of SI, indicating a higher degree of cortical reorganization. No such correlation could be found for the pain level experienced on the day of SSEP mapping and the degree of immobilization.

Tecchio and co-workers investigated hand somatotopy of SI in patients with carpal tunnel syndrome. When pain symptoms dominated the clinical picture, representation of the affected hand was restricted. However, in the case of prevailing paresthesias, an enlarged representation was observed. These findings suggest a substantial restriction

Table 1 Clinical and electrophysiological data of CRPS patients. Mean pain intensity (VAS values: 0 = no pain to 10 = most extreme pain) based on the averaged pain intensity during the last 4 weeks before SSEP measurement

Patient	Sex	Age (years)	Affected side	CRPS initiated by	Duration of CRPS (months)	Acute pain intensity (VAS)	Mean pain intensity (VAS)	Degree of immobilization (%, 0 = no immobilization, 100 = complete immobilization)	Differences of polar angles ("median-minus ulnar-angle"; degrees): CRPS	Differences of polar angles ("median-minus ulnar-angle"; degrees): control
1	M	21	Right	Minor trauma	3	2.5	1.0	100	2.93	3.91
2	M	46	Left	Radial fracture	12	2.1	1.8	40	0.94	1.31
3	M	64	Left	Minor trauma	2	2.3	4.1	40	0.72	2.49
4	M	52	Left	Radial fracture	1	1.3	3.8	60	1.61	4.26
5	F	52	Right	Ulnar fracture	2	3.0	3.0	30	1.35	3.02
6	F	29	Left	Minor trauma	8	2.8	2.9	95	1.5	3.62
7	F	19	Right	Minor trauma	12	7.6	5.6	30	0.32	4.02

of SI representation subsequent to a painful peripheral nerve lesion (Tecchio et al. 2002).

In amputees, changes in cortical reorganization mirrored a pain-correlated displacement of the lip's representational field contralateral to the amputated limb, indirectly indicating a restricted SI representation (Flor et al. 1995; Birbaumer et al. 1997). The main difference from our study is that the results in amputees were found in patients with complete loss of peripheral nerves, whereas in CRPS I a peripheral nerve lesion has to be excluded (Stanton-Hicks et al. 1995).

In CRPS I, many clinical symptoms can be explained by a central nervous system pathophysiology (Thimineur et al. 1998; Sieweke et al. 1999; Riedl et al. 2001). Changes in somatosensory (Rommel et al. 2001), autonomic (Wasner et al. 1999; Baron et al. 2002) and motor processing (Galer and Jensen 1999; van Hilten et al. 2001) have been discussed as possible mechanisms in the development of CRPS. Juottonen and co-workers recently reported altered somatosensory processing in six patients with CRPS type I (Juottonen et al. 2002). Using the method of whole-head MEG, they found a significantly shortened distance between SI representation of thumb and little finger on the affected hemisphere indicative of a shrinkage of the cortical hand representation. However, size of cortical representations contralateral to the CRPS-affected hand did not correlate with the individual pain levels obtained once before MEG measurement. Our findings corroborate these observations regarding an overall reduction of the size of the affected hand representation, and a lack of correlation between the amount of reorganization and current pain levels assessed briefly before mapping.

However, patients suffering from CRPS I characteristically exhibit a distinctive day-by-day variation of their current pain intensity (see also Table 1; cf. current and mean pain intensities). We therefore assume that the ongoing nociceptive inputs arising from chronic pain might be causally related to reorganizational processes in the somatosensory cortex. In fact, using the parameter of mean subjective pain levels experienced over several weeks instead of the pain levels assessed only once, immediately before SSEP mapping, we found a significant correlation between mean pain intensity and the alterations of the contralateral SI representation. Thus, mean pain intensity of the individual patient appears to be a valid predictor for the amount of cortical reorganization.

In functional magnetic resonance imaging studies, proprioception seems to be an important source of contralateral SI signal (Rausch et al. 1998). To evaluate the influence of the reduced use of the painful hand as a self-protection mechanism and the origin of reduced proprioception, we asked our patients to estimate the degree of immobilization of the CRPS-affected hand during the last 4 weeks (Table 1). Using non-parametric correlation analysis, there was no correlation between the degree of immobilization and the side-to-side differences in the hand representation in SI. These findings support our hypotheses that increased nociceptive inputs seem to

be the major cause for the diminished hand representation in SI contralateral to the affected side. However, we cannot completely exclude that a pain dependently altered use of the affected hand might have contributed to our results.

Conclusions

We found a close relationship between the reorganization processes of the somatosensory cortex and the increased sustained nociceptive inputs to painful CRPS-type-I-affected limbs, probably reflecting two, not mutually exclusive, mechanisms: (1) persistent nociceptive inputs might interfere with cortical relays of sensory perception, progressively decreasing representational area of the pain-affected limb, and (2) a presumable suppression of SI activity might per se sustain the experience of pain.

Follow-up studies using modern functional imaging methods are necessary to provide a deeper insight into the role of the somatosensory cortex in the rise and maintenance of CRPS-associated pain.

Acknowledgements. This work was supported by grants from the Richard Sackler Foundation (B.V. and C.M.), from the Hauptverband der gewerblichen Berufsgenossenschaften, Germany (M.Z. and M.T.), and in part by a grant from the BMBF (NR. 01EM0102). We thank Mr. Steve Langan for his skillful editing of the manuscript.

References

Baron R, Wasner G (2001) Complex regional pain syndromes. Curr Pain Headache Rep 5:114–123

Baron R, Schattschneider J, Binder A, Siebrecht D, Wasner G (2002) Relation between sympathetic vasoconstrictor activity and pain and hyperalgesia in complex regional pain syndromes: a case-control study. Lancet 359:1655–1660

Birbaumer N, Lutzenberger W, Montoya P, Larbig W, Unertl K, Topfner S, Grodd W, Taub E, Flor H (1997) Effects of regional anesthesia on phantom limb pain are mirrored in changes in cortical reorganization. J Neurosci 17:5503–5508

Birklein F, Handwerker HO (2001) Complex regional pain syndrome: how to resolve the complexity? Pain 94:1–6

Bruehl S, Harden RN, Galer BS, Saltz S, Backonja M, Stanton-Hicks M (2002) Complex regional pain syndrome: are there distinct subtypes and sequential stages of the syndrome? Pain 95:119–124

Flor H, Elbert T, Knecht S, Wienbruch C, Pantev C, Birbaumer N, Larbig W, Taub E (1995) Phantom-limb pain as a perceptual correlate of cortical reorganization following arm amputation. Nature 375:482–484

Flor H, Braun C, Elbert T, Birbaumer N (1997) Extensive reorganization of primary somatosensory cortex in chronic back pain patients. Neurosci Lett 224:5–8

Galer BS, Jensen M (1999) Neglect-like symptoms in complex regional pain syndrome: results of a self-administered survey. J Pain Symptom Manage 18:213–217

Juottonen K, Gockel M, Silen T, Hurri H, Hari R, Forss N (2002) Altered central sensorimotor processing in patients with complex regional pain syndrome. Pain 98:315–323

Rausch M, Spengler F, Eysel UT (1998) Proprioception acts as the main source of input in human SI-activation experiments: a functional MRI study. Neuroreport 9:2865–2868

Riedl B, Beckmann T, Neundorfer B, Handwerker HO, Birklein F (2001) Autonomic failure after stroke—is it indicative for pathophysiology of complex regional pain syndrome? Acta Neurol Scand 103:27–34

Rommel O, Malin J, Zenz M, Janig W (2001) Quantitative sensory testing, neurophysiological and psychological examination in patients with complex regional pain syndrome and hemisensory deficits. Pain 93:279–293

Schott GD (2001) Reflex sympathetic dystrophy. J Neurol Neurosurg Psychiatry 71:291–295

Schwartzman RJ (1993) Reflex sympathetic dystrophy. Curr Opin Neurol Neurosurg 6:531–536

Sieweke N, Birklein F, Riedl B, Neundorfer B, Handwerker HO (1999) Patterns of hyperalgesia in complex regional pain syndrome. Pain 80:171–177

Stanton-Hicks M, Janig W, Hassenbusch S, Haddox JD, Boas R, Wilson P (1995) Reflex sympathetic dystrophy: changing concepts and taxonomy. Pain 63:127–133

Tecchio F, Padua L, Aprile I, Rossini PM (2002) Carpal tunnel syndrome modifies sensory hand cortical somatotopy: a MEG study. Hum Brain Mapp 17:28–36

Thimineur M, Sood P, Kravitz E, Gudin J, Kitaj M (1998) Central nervous system abnormalities in complex regional pain syndrome (CRPS): clinical and quantitative evidence of medullary dysfunction. Clin J Pain 14:256–267

van Hilten JJ, van de Beek WJ, Vein AA, van Dijk JG, Middelkoop HA (2001) Clinical aspects of multifocal or generalized tonic dystonia in reflex sympathetic dystrophy. Neurology 56:1762–1765

Veldman PH, Reynen HM, Arntz IE, Goris RJ (1993) Signs and symptoms of reflex sympathetic dystrophy: prospective study of 829 patients. Lancet 342:1012–1016

Wasner G, Heckmann K, Maier C, Baron R (1999) Vascular abnormalities in acute reflex sympathetic dystrophy (CRPS I): complete inhibition of sympathetic nerve activity with recovery. Arch Neurol 56:613–620